

# ENDOSCOPIC THIRD VENTRICULOSTOMY

---

# Introduction

- Endoscopic third ventriculostomy is a technique to treat non communicating hydrocephalus.
- Involves making a hole in the floor of the third ventricle to bypass the obstruction to CSF flow
- Involves using an endoscope, (rigid or flexible)

# History

- L'Espinasse, in 1910, used a cystoscope to perform fulguration of the choroid plexus
- Dandy refined this method calling it “ventriculoscopy”
- In 1922, he described the use of an endoscope to perform choroid plexectomy.
- **Mixter** in **1923** performed the **first ETV** in a child with congenital hydrocephalus using a **urethroscope** and probe.

# History

- Popularity of ETV waned because of high mortality, large cumbersome instruments, poor magnification and illumination.
- In mid 1980's minimally invasive neurosurgery became popular leading to a renewed interest in ETV and neuroendoscopy.
- Advances, which brought together brighter light sources and cameras with improved resolution, were an important part of the rediscovery of neuroendoscopy.

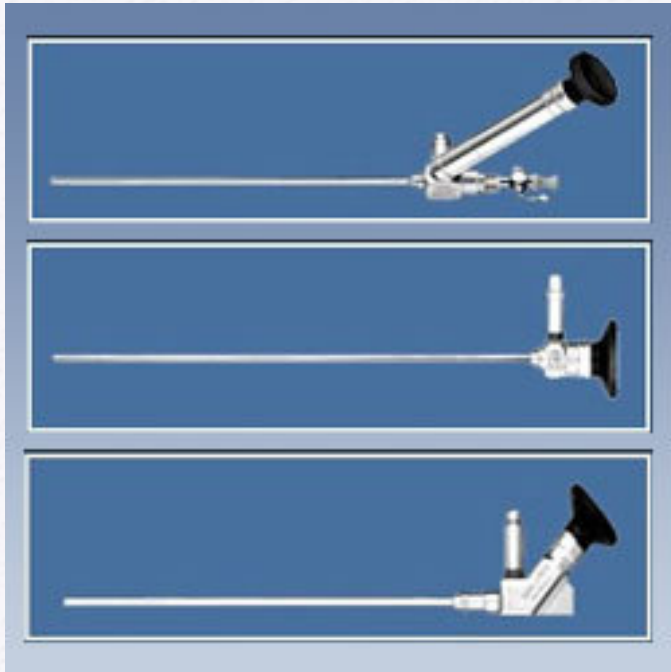
# Operative Technique

Tools

Endoscopic Anatomy

• Technique

# Technique: Tools



# Comparison of rigid and flexible scopes

	Rigid scopes	Flexible scope
<b>Advantages</b>	Better image	Steerability
	Higher resolution	
	Wider view	
	Better colour	
	Better light transmission	
<b>Disadvantages</b>	Less maneuverable	Poor image
		Less true colour
		Poor light
		Limited selection of scopes and instruments
		Narrower view
		Smaller working channel

# Indications - Common

- Primary Aqueductal Stenosis

- Most common indication

- Pineal and Tectal Tumors with HCP

- One step procedure to include ETV and biopsy

- Risk: Case reports of germinoma recurring along ventriculoscope tract

- Wellon et al., reported 13 patients with tectal plate gliomas and HCP. All underwent ETV with symptoms resolved at 31 months



# Indications - Common

- Idiopathic Stenosis of foramen of Magendie and Luschka

- Several case reports reporting successful management of hydrocephalus

- Posterior Fossa Tumors

- Saint Rose et al., performed ETV prior to posterior fossa surgery. They found that this significantly reduced risk of postoperative HCP.

- Patients with repeated shunt infections

# Indications - Uncommon

- Isolated Lateral Ventricle with hydrocephalus

- ETV in combination with septal fenestration

- Dandy Walker

- Case reports of performing ETV and placing a stent from the 3rd ventricle to the posterior fossa cyst.

Successful in two patients, failed in one.

- Slit Ventricle Syndrome

- Case reports

# Indications - Uncommon

- **Communicating Hydrocephalus**

- Indications not clearly defined or understood
- Some reports of improved symptoms, thought to be due to a functional obstruction
- Feng Hailong et al , J Neurosurg 2008, 32 patients with 65.6 % success

# Indications

High success rate  
(>75 %)

- Acquired aqueductal stenosis
- Tumor obstructing CSF flow

Intermediate success  
rates  
(50-75 %)

- Previously shunted MMC
- Congenital aqueductal stenosis
- Arachnoid cyst/ Dandy walker
- Recurrent shunt infections/  
malfunction

Low success rates  
(<50 %)

- Post hemorrhagic HCP
- Post infectious HCP
- MMC

# Favourable features for ETV

## Clinical

- Age > 6 months at the time of diagnosis of HCP
- Age > 6 m at the time of procedure
- No prior radiation therapy
- No h/o meningitis/hemorrhage

## Radiological

- Obstructive HCP
- Lack of aqueductal flow void
- Thinned floor of 3<sup>rd</sup> ventricle
- Downward bulging floor

# Basic Operative Technique

- Determine entry point and enter ventricular system
- Finding and entering the Foramen of Monro
- Inspecting the floor of the third ventricle
- Perforating the floor of the third ventricle
- Enlarging the perforation (approx 5 mm)
- Inspecting the pre-pontine cistern

# Targeting: Freehand Method

## Non Stereotactic Method – Freehand Method

- Preoperative MRI evaluation of neurovascular structures below floor
- Burr hole 1 cm in front of the palpated coronal suture and at mid-pupillary line, approx 2-3 cm lateral to midline
- Aim endoscope medially toward medial canthus of ipsilateral eye

*Hellwing et al, Neurosurg Rev 2005*

# Targeting : Stereotactic Method

## Stereotactic Method – Neuronavigation

- Allows for optimal burr hole position
- Helps to reduce traction on foramina of Monro-related structures
- Kelly et al., described stereotactic third ventriculostomy in 1986
- Target Point: Point in the midline between dorsum sellae and the basilar artery
- Entry Point: Foramen of Monro (side of entry). Extend line to skin for skin entry point



# Technique: Introduce Endoscope

- Position – The head is slightly flexed in a sniffing position.
- Dura is cut in a cruciate fashion
- Pass a 14 French trocar into lateral ventricle
- Introduce endoscope through the sheath and navigate through the Foramen of Monro
- Identify structures on floor of 3rd ventricle

# Technique: Fenestration

- The correct point for the third ventriculostomy is the centre of so-called hypophysiomaillary triangle.
- Multiple methods exist for perforating the floor including:
  - Blunt probe
  - Electro-coagulation and cutting probes
  - Laser probe
  - Ultrasonic contact probe
- Dilation of the fenestration is achieved using a Fogarty balloon catheter

# Technique

- Continuous irrigation with lactated Ringer's solution heated to 37.5°C temperature
- Ventriculomegaly in patients who have undergone ETV decreases at a much slower rate and to a much less extent than in patients with implanted shunts.
- Therefore, NCCT is performed at 6 to 8 weeks rather than on postoperative day 1 as is in practice in patients with shunts.

# Technique: Fenestration

- Must explore the pre-pontine space and open membrane of Liliequist for a successful ETV.
- Liliequist membrane extends from the upper border of dorsum sellae to the anterior edge of mamillary bodies.

# Complications

## Intra operative

Bradycardia – Incidence  
as high as 41%

IVH - Choroid plexus  
injury

**Basilar artery injury**  
**– incidence 0.05 %**

## Postoperative

Hypothalamic dysfunction

Pneumocephalus

Subdural hygromas  
hematomas

Infection

CSF leak from wound

Memory dysfunction

Midbrain injury

## Delayed

Seizures

Late failure of ETV –

**Sudden deaths**

	Jenkinson et al.	Gangemi et al.	Drake	Hader et al.
AGE	Adult	NPH only	0-20 yrs	All
No of patients	190	110	368	131
CSF LEAK (%)	1	1.8	3.6	6.1
MENINGITIS (%)	0	-	2.8	5.3
HEMORRHAGE (%)	2	3.6	1.4	2.3
HYPOTHALAMIC INJURY	—	—	1.4	6.1
SEIZURE (%)	—	—	3.75	1
DEATH (%)	0	0	0.5	—
WOUND INFECTION	—	1	—	1.5
OVERALL COMPLICATION	5.8	6.4	13.6	16

# Measurable Outcomes in Literature Review

- Shunt Independence
- Change in ventricular size
- Patency of stoma

# Outcomes

Author	N	Age	Mean follow up	Success
Oumar Sacko et al (France) <i>J Neurosurg</i> , 2010	368	35 years (2 days–88 years) <b><u>47% &lt; 18 years</u></b>	47 months (6–106 months)	68.5%
Michael D. Jenkinson (UK) <i>J Neurosurg</i> , 2009	129	43 years (18–79 years) <b><u>All &gt; 18 yrs</u></b>	36 months (1–96 months)	83%
Hailong Feng et al (China) <i>J Neurosurg</i> 2004	58	35 years (5-67 years)	24 months (3 to 41 months)	84%
Anil Garg et al (India) <i>Pediatr Neurosurg</i> 2009	115	38 % < 1 yr 48% < 2 yr	10.6 months (3–51 months)	86.1%



# Outcomes

- **Feng et al.** *ETV in the management of obstructive hydrocephalus. J Neurosurg, 2004.*
- Method
  - Retrospective analysis
  - 58 patients in one institution between 1999-2003
  - Mean age 35 years ( 5-67 yrs)
  - Mean follow-up 24 months

# Adult Outcomes

- Results
  - At one month, 45/58 (77.6%) patients had improvement in clinical outcome
  - Early postoperative improvement (within 2 weeks after ETV, and a patent stoma on cine phase–contrast magnetic resonance (MR) images were significant prognostic factors for a successful ETV.
  - **No predictive value** of reduced ventricle size on MRI **within 2 weeks**, however, it was significant in predicting good outcome at 3 months and 6 months

# Pediatric Outcomes

- *Drake et al*, *Endoscopic Third Ventriculostomy in Pediatric Patients: The Canadian Experience*, *Neurosurgery*, 2007
- 15 year period, **368 patients**
- – **Average age 6.5 years**, 1 day to 20 years, median age 4.8 yr
- 70 % patients were <10 years
- 34% due to aqueductal stenosis, 29% due to tumor
- 22% had been previously shunted
- The **1- and 5-year** success rates were **65 and 52%**, respectively.

# Infant Outcomes

Author	Age group	No of patients	Follow up	Succes Rate
<i>Hideki Ogiwara et al (US)</i> <i>Childs Nerv Syst (2010)</i>	< 6 m	23	57.4 m	34.8%
<i>Radim Lipina et al (Czech)</i> <i>Childs Nerv Syst (2008)</i>	< 6 m	14	21 m	57%
<i>Baldauf et al., (Germany)</i> <i>Child Nervous System,</i> <i>2007</i>	<15 m	21	26.2 m	43%
<i>Dorothee Koch et al,</i> <i>(Germany)</i> <i>Childs Nerv Syst (2006)</i>	<1 yr	28	25 m	46%
<i>Anil Garg et al (India)</i> <i>Pediatr Neurosurg 2009</i>	All	38 (< 1 yr)	10.6 m	71%

# Long Term Outcomes

- *Kadrian et al. Long Term Reliability of ETV. Neurosurgery, 2005.*
  - Retrospective analysis
  - 181 patients (203 procedures) from one institution over 22 years, from 1979 to 2001
  - Age range 2 days to 78 years
  - 54/118 (54%) patients less than 2 years old
  - Surgical success: probability of performing an successful ETV was 89%

# Long Term Outcomes

- Reliability of ETV after **1 year** was stratified according to age.
  - 0-1 month: 31 % success
  - 1-6 months: 50% success
  - 6-24 months: 71% success
  - Greater than 24 months: 84%
- 16 patients had ETV revisions with a success rate of 65% at four year follow-up.

# ETV following VPS malfunction

- *Woodworth et al, Neurol Res, 2007*
- 11 patients underwent ETV at VPS failure
- Compared to patients who underwent ETV as primary procedure (16 patients)
- 71% of patients experienced immediate improvement, but **only 25% remained recurrence free at 2 years.**
- ETV after shunt failure was 2.5 fold more likely to fail

# Evaluating Patency of ETV

- This has been a challenging problem especially in cases where the clinical course is unclear
- **Cine phase contrast** MRI is able to detect flow across ETV

Minor flow appears to be an early sign of closure

- **Fast spin-echo T2 (FSE)**



# ETV Patency on Imaging

- *Bargallo et al., AJNR, 2005*
- Goal: To determine the utility of **cine phase contrast** MR imaging
- 25 patients reviewed at one year
- Results
  - Restoration of pulsatile motion of CSF circulation observed post operatively.
  - The stroke volume registered at ventriculostomy was maintained with time.
  - There was no relationship between ventricular size changes and clinical outcome.

# ETV failure

## Follow-up for 5-6 years

- Maximum incidence of failure: first 1-2 months

## Early : within 4 wks

- Non-absorption from arachnoid granulation despite good MRI flow

## Delayed : after 4 wks

- Stoma closure gliosis (6-15%)

Jones et al Min. Inv. Tech NS 1993  
Siamin et al Childs Nervous System 2001  
Cinalli et al Min. JNS 1999

# Repeat ETV for Failures

20 patients underwent repeat ETV

- Age ranged from 8 months to 53 years
- Intraoperative finding at repeat ETV
  - 1. Occlusion by scar (10 cases)
  - 2. Virginal floor of the third ventricle (5 cases)
  - 3. Pinhole ventriculostomy (3 cases)
  - 4. Incompletely penetrated membrane (1 case)
  - 5. Blood clot occluding orifice (1 case)
- Repeat ETV successful in 65% of patients

**Sioman et al., CNS, 2001**

# ETV Failures

- Failure of ETV in infants has been studied by repeat ETV
  - 1) Reclosure of the ventriculostoma;
  - 2) Narrowing of the ventriculostoma; and
  - 3) patent ventriculostoma with new arachnoid membranes in the basal cisterns below the floor of the third ventricle, not present at the time of the first ETV

Wagner et al, J Neurosurg, 2005

## Assessment of the influence of operative factors in the success of endoscopic third ventriculostomy in children

- Following surgical factors did not correlate with success of ETV:
  - ✓ intraoperative haemorrhage during ETV,
  - ✓ presence of haemosiderin deposits indicating previous haemorrhage
  - ✓ double floor of third ventricle,
  - ✓ presence of pre-pontine adhesions,
  - ✓ Thickness of floor of third ventricle
- CSF leak was correlated with previous CSF infection ( $p=0.013$ ), indicating that previous CSF infection predisposes towards CSF leak

# ETV in TBM hydrocephalous

- *Husain M et al et al, Neurosurg Rev. 2005*
- 28 patients (15 males and 13 females)
- Average age 23 years
- Outcome was satisfactory in 14 (50%), acceptable in five (18%) and unsatisfactory in nine (32%) patients

# ETV in TBM hydrocephalous

Author	No of patients	Success rate
<i>Figaji et al</i> <i>Childs Nerv Syst</i> (2003)	2 pateints	100 % at 1 month
<i>Raj Shekhar et al</i> <a href="#"><u>Surg Neurol.</u></a> 2005	2	100 % at 3 yrs
<i>Mazhar Husain et al</i> <i>Neurosurg Rev</i> (2005)	28	50% at 1 year
<i>Figaji et al</i> <i>Childs Nerv Syst</i> (2007)	17	41% at 1 year

# ETV in NPH

- *Michelangelo Gangemi et al , Neurosurgery 2004*
- Retrospective study
- Of the 25 patients, 18 were men and 7 were women,
- Age from 53 to 75 years (mean, 69 yr).
- Rate of neurological improvement after ETV in this series was 72%
- The improvement of gait disturbance was significantly higher (73%) as compared with that of dementia (16%) and urinary incontinence (31%).



# ETV in NPH

- For this reason, ETV is advised in patients with a clinical evolution of no more than 1 year before the diagnosis
- The indications for ETV in patients with INPH may be based on two main clinical criteria: short preoperative evolution and significant prevalence of gait disturbances with little or no dementia.

# ETV with CPC

Procedure & Significance	Patient Age		Total
	< 1 Yr	≥ 1 Yr	
ETV only			
no. of successes (%)	98 (47)	47 (80)	145 (54)
total procedures	209	59	268
ETV-CPC			
no. of successes (%)	141 (66)	33 (80)	174 (68)
total procedures	214	41	255
p value	<0.0001	1.000	0.0012

The overall surgical mortality rate was 1.3%, and the infection rate was less than 1%.

**BENJAMIN C. WARF, M.D. , J Neurosurg Pediatrics, 2005**

# ETV with CPC in MMC patients with HCP

- 115 patients
- 93 completed ETV-CPC with > 1 month of follow-up.
- Successful in 71 patients (76%), with a mean and median follow-up of 19.0 months.
- The operative mortality rate was 1.1%, and there were no infections

**Benjamin C. Warf, J Neurosurg  
Pediatrics, 2008**

# Endoscopic Third Ventriculostomy

5 Years' Experience at the All India Institute of Medical Sciences

A. Garg A. Suri P.S. Chandra R. Kumar B.S. Sharma A.K. Mahapatra

Department of Neurosurgery, Neurosciences Centre, All India Institute of Medical Sciences, New Delhi, India

## Abstract

Endoscopic third ventriculostomy (ETV) is one of the efficacious surgical options available for obstructive hydrocephalus, and is preferable to a ventriculoperitoneal shunt in those eligible. We retrospectively studied 115 cases, who underwent ETV at our institute over the last 5 years. Thirty-eight patients were infants. Major indications for ETV were aqueductal stenosis (n = 60/115, 52.2%), Dandy-Walker malformation (15/115, 13%), associated arachnoid cyst (n = 13/115, 11.3%) and post-meningitic hydrocephalus (n = 12/115, 10.4%). Average duration of the follow-up was 10.6 months. Ninety-nine patients (86.1%) showed clinical improvement after surgery. Clinical improvement was seen in 27 out of 38 infants (71%) followed up. ETV is a highly effective tool in all age groups of patients for the management of hydrocephalus. Clinical features should be considered as indications of the success or failure of ventriculostomy in infants who have low-pressure hydrocephalus.

Copyright © 2009 S. Karger AG, Basel

# New Concepts

- Robot assisted ETV:
  - Robot “Evolution 1”
  - Used for robot-assisted navigated ETV in six patients with aqueductal stenosis
  - ETV initially successful in all patients

*Zimmerman et al. Acta Neurochir, 2004*

A wide-angle photograph of a large, modern university building with a prominent green lawn in the foreground. The building is multi-storied, constructed of brick, and features a central section with a green and blue facade. Numerous palm trees are planted in rows across the lawn. The sky is clear and blue. In the bottom right corner, there is a cluster of yellow marigold flowers.

*Thank you for your attention*